

Prospective Study

Transforaminal Epiduroscopy in Patients with Failed Back Surgery Syndrome

Martín Avellanal, MD, PhD^{1,2}, Gonzalo Diaz-Reganon, MD^{1,2}, Alejandro Orts, MD^{1,2}, Lucio Gonzalez-Montero, MD^{1,2}, and Irene Riquelme, MD^{1,2}

From: ¹Pain Clinic, Hospital Universitario Sanitas La Moraleja, Madrid, Spain; ²Consultores en Dolor, Madrid, Spain

Address Correspondence:
Martín Avellanal, MD, PhD
c/ Sagasta, 16.
28004 Madrid, Spain
E-mail:
mavellanal@telefonica.net

Disclaimer: There was no external funding in the preparation of this manuscript. Conflict of interest: Each author certifies that he or she, or a member of his or her immediate family, has no commercial association (i.e., consultancies, stock ownership, equity interest, patent/licensing arrangements, etc.) that might pose a conflict of interest in connection with the submitted manuscript.

Manuscript received: 05-16-2018
Revised manuscript received:
06-21-2018
Accepted for publication:
07-25-2018

Free full manuscript:
www.painphysicianjournal.com

Background: Epiduroscopy is a useful diagnostic and therapeutic tool for managing failed back surgery syndrome (FBSS). The conventional approach is via either the sacral hiatus or the interlaminar. Major causes of FBSS include epidural fibrosis, disc herniation, and stenosis. When these problems are located at the intervertebral foramen level, it can be difficult to reach the lateral recess and the foramen with the epiduroscope. Transforaminal epiduroscopy could be a useful alternative approach in patients with FBSS located at the foraminal level.

Objective: We present a new procedure for lumbar epiduroscopy via a transforaminal approach and its application in patients with FBSS. The technique is described and long-term results are reported.

Study Design: This study used a single-arm prospective observational design.

Setting: The research took place at the University Hospital in Spain.

Methods: Patients with FBSS suffering severe chronic radicular pain (Numeric Rating Scale [NRS-11] > 7) who had not responded to other treatments were included. Selective root stimulation during a pulsed radiofrequency procedure confirmed the origin of pain by means of an exact reproduction of typical pain. Transforaminal epiduroscopy was performed at the affected level. The severity of fibrosis observed was recorded. The NRS-11 score was reevaluated at 1, 6, and 12 months after the procedure. Any complications related to the treatment were recorded.

Results: Twenty-four patients were included. The mean number of back surgeries was 1.66 (range, 1-5). The basal NRS-11 score was 7.83 (0.14); at 1 month, 3.66 (0.38) ($P < 0.001$); at 6 months, 4.46 (0.48) ($P < 0.01$); and at 1 year after treatment, 4.17 (0.51) ($P < 0.01$). Most patients (54%; 95% CI, 34%-74%) obtained > 50% pain reduction on the NRS-11, maintained during a 1-year follow-up period. No major complications were registered.

Limitations: The research was limited by the lack of a control group.

Conclusions: We have described a new procedure for epiduroscopy via the transforaminal approach. It is a useful and safe approach to managing FBSS at the foraminal level and shows better long-term results than other endoscopic procedures.

Key words: Epidural, epiduroscopy, chronic pain, spinal cord, back surgery

Pain Physician 2019; 22:89-95

The first attempt to visualize the human epidural space is attributed to Michael Burman. As early as 1931, he examined the anatomy of cadaveric vertebral columns with the arthroscopic equipment available at that time (1). In 1938, the American neurosurgeon J. Lawrence Poole reported the first endoscopic approach to the cauda equina performed on a live patient one year earlier (2). Then, after little

or no progress until the 1970s, Ooi et al reported their evaluations with various fiber-optic systems (3). These early spinal endoscopies should be more properly considered as myeloscopies, given that they specifically inspected the intrathecal space for diagnostic and investigational purposes.

In the 1980s, Blomberg began using this technique to study the epidural space, and the name "epiduroscopy" appeared for the first time in describing this procedure (4).

In the 1990s, the first flexible, small-diameter, fiber-optic systems were developed; Heavner et al (5) and Shimoji et al (6) published their first observations in 1991. In 1995, Saberski and Kitahata improved the technique and described the conventional caudal approach (7). Then in 2008, Avellanal and Diaz-Reganon introduced a new procedure for performing interlaminar (anterograde or retrograde) epiduroscopy (8).

Today, epiduroscopy has developed from a valuable diagnostic procedure to a therapeutic tool included in algorithms for managing failed back surgery syndrome (FBSS) (9,10) with a low morbidity rate (11).

Major causes of FBSS include epidural fibrosis, disc herniation, and stenosis. When these problems are located at the intervertebral foramen level, it can be difficult to reach the lateral recess and the foramen using the caudal or interlaminar approaches. Thus, transforaminal epiduroscopy could be a useful alternative approach for patients with FBSS located at the foraminal level.

We present a new procedure for lumbar epiduroscopy via a transforaminal approach and its application in patients with FBSS. The technique is described and long-term results are reported.

METHODS

This was a prospective observational study. The protocol was approved by the institutional review board of our hospital and was included as a modified approach to epiduroscopy. Written informed consent was obtained from the patients. There was no external funding or conflict of interest within the team.

The procedure was performed on 26 patients (aged 18 or older) with FBSS suffering severe unilateral chronic sciatica (Numeric Rating Scale [NRS-11] > 7), which is defined as pain in the distribution of a lumbar nerve root. The duration of the pain was at least 6 months from the last surgery. The patients had received conventional FBSS algorithmic treatment, including multimodal

analgesia (with nonsteroidal anti-inflammatory drugs [NSAIDs], opioids, and coadjuvants), physical therapy, epidural steroids, epidurolysis, and dorsal root ganglion pulsed radiofrequency (10), without response. Selective root stimulation during a pulsed radiofrequency procedure would have confirmed the origin of pain by means of an exact reproduction of typical pain.

Electromyography and lumbar magnetic resonance imaging (MRI) (or computed tomography [CT] when in doubt) must have been recently performed (ideally within the prior 2 months).

The severity of fibrosis observed during epiduroscopy was recorded according to the Bosscher and Heavner classification (grade 1: loose strings and sheets of fibrosis; grade 2: more organized, continuous sheets and strings of fibrous material, not giving resistance to the scope; grade 3: dense continuous fibrous material, the scope can only be advanced with difficulty; grade 4: dense continuous fibrous material, the scope cannot be advanced) (12).

The NRS score was re-evaluated at 1, 6, and 12 months after the procedure. Any complications related to the treatment were recorded.

Exclusion criteria were similar to other epiduroscopy approaches: pregnancy, coagulation disorders, severe glaucoma, malignancy, allergy to radio-opaque contrast medium, local anesthetics, use of steroids or hyaluronidase, progressive motor disorders, incontinence, a history of cerebrospinal fluid fistula, and post-surgical meningocele.

Treatment success was defined as > 50% pain relief maintained at one year of follow-up. Statistical analysis of the NRS-11 results was performed using Friedman's test. Data are expressed as mean (SEM or range) or percentage (95% confidence interval [CI]), when appropriate.

Transforaminal Epiduroscopy Procedure

The patient must be laid prone on a translucent x-ray table, with a pillow placed under the pelvis to minimize lumbar lordosis when needed. Intravenous (IV) access is established and 2 g cefazolin administered. "Conscious" or light sedation with IV midazolam 0.05 to 0.1 mg/K is performed. After sterile preparation of the surgical field, fluoroscopy is used to locate the lumbar space (L3–L4, L4–L5 or L5–S1). The skin and underlying tissue are anesthetized with lidocaine 2%. After that, a 14-gauge RX Coudé epidural needle (Epimed International, Johnstown, NY) is introduced 8 to 12

cm paramedial with a 30° to 45° angulation ideally directed to the suprapedicular level of the target intervertebral foramen (Fig. 1). Anteroposterior, oblique, and lateral fluoroscopic views must be combined to guide the advancement of the needle. The tip of the needle must be as near as possible to the foramen without puncturing it. A correct position is confirmed by injection of contrast medium showing the affected lumbar nerve root. At this time, a 0.77-mm flexible PolyScope fiberscope (PolyDiagnost GmbH, Pfaffenhofen/Ilm, Germany) covered with a TEMPO 4F vertebral 135° angiographic catheter (Cordis Corporation, Miami, FL), which is connected to a Y-adaptor/hemostasis valve (Merit Medical Systems, South Jordan, UT) for fluid administration, can be advanced under direct vision and fluoroscopy guidance to the epidural space in a cephalad direction parallel to the affected root, usually reaching the anterior epidural space (Fig. 2). If the study reveals fibrosis or adhesions at the suspected nerve root, attempts are made to break adhesions down using saline boluses or by means of the tip of the endoscope (Fig. 3). Then, a mixture of 40 mg triamcinolone, 600 IU hyaluronidase, and 0.0625% bupivacaine is injected. The total volume of saline is limited in our epiduroscopic treatments to 60 mL, but if the patient reports transient neurological symptoms (headache, hypoacusia, visual impairment), the procedure must be immediately ended.

These procedures were performed as ambulatory interventions and undertaken in the day-stay unit.

RESULTS

The initial study population consisted of 26 patients. Two patients did not complete the 1-year follow-up and were thus not included in the study.

Over 54% of the participants were men, and the mean age was 59.7 (range, 40–84) years. The mean number of back surgeries was 1.66 (range, 1–5). The basal NRS-11 score was 7.83 (0.14); at 1 month, 3.66 (0.38) ($P < 0.001$); at 6 months, 4.46 (0.48) ($P < 0.01$), and at 1 year after treatment, 4.17 (0.51) ($P <$

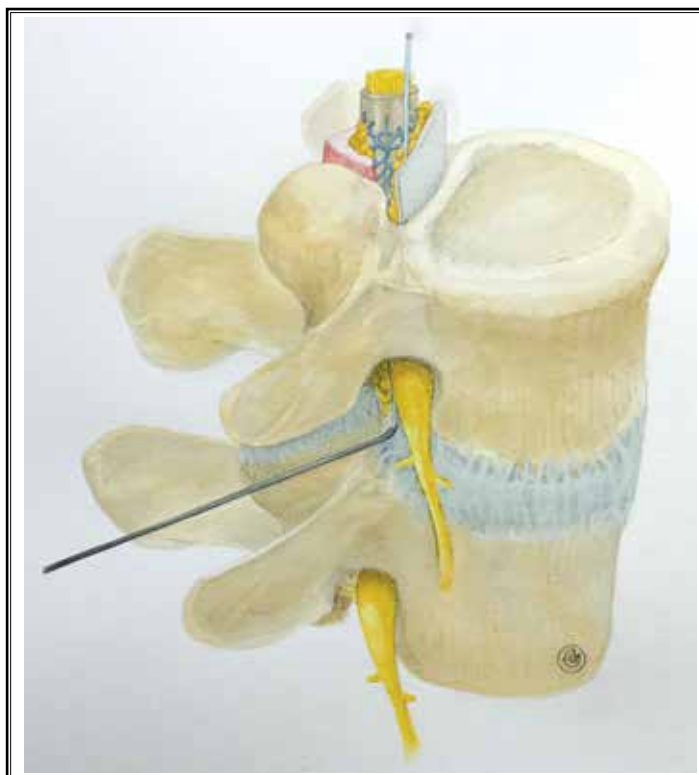


Fig. 1. Picture showing the proposed transforaminal approach to epiduroscopy.

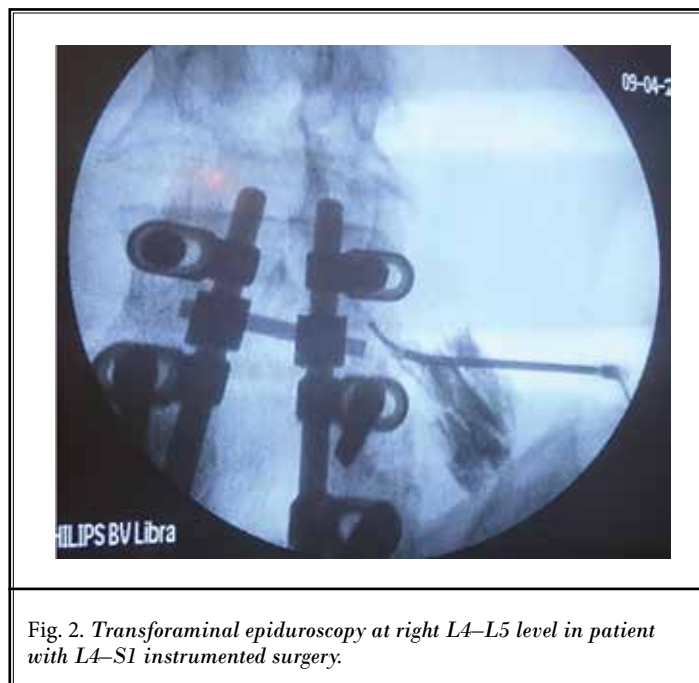


Fig. 2. Transforaminal epiduroscopy at right L4–L5 level in patient with L4–S1 instrumented surgery.

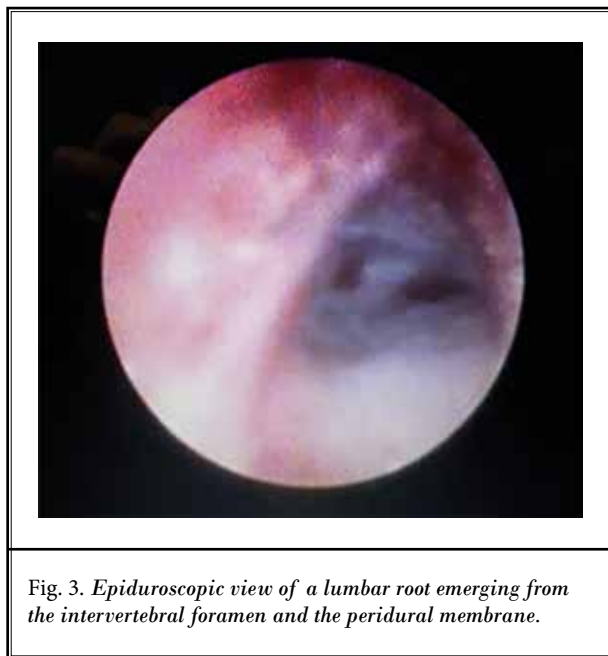


Fig. 3. Epiduroscopic view of a lumbar root emerging from the intervertebral foramen and the peridural membrane.

0.01). No differences were found among NRS-11 values at 1, 6, and 12 months. The mean duration of the procedure was 28.3 (15–40) minutes. The volume of fluid administered was 37 (22–55) mL (Table 1).

Most patients (54%; 95% CI, 34%–74%) obtained significant pain relief (> 50% pain reduction in NRS-11, maintained during a 1-year follow-up period). On the other hand, 4 patients (16.7%; 95% CI, 1.8%–31.6%) required surgical reoperation; 3 patients (12.5%; 95% CI, 0.0%–25.7%) were submitted to spinal cord stimulation (SCS); and 4 patients (16.7%; 95% CI, 4.6%–37.1%) continued with palliative multimodal analgesia.

Transforaminal approaches were performed at the L5–S1 level (45.8%) and the L4–L5 level (41.7%). Only 12.5% of approaches were made at the L3–L4 level. The right side was twice as common as the left one.

The severity of fibrosis found during epiduroscopy was described as grade 3 in 62.5% (95% CI, 43%–82%) of the patients, grade 4 in 33.3% (95% CI, 14.5%–52.2%), and grade 2 in 4.2% (95% CI, 0%–20%).

No major complications occurred in any case. All procedures were ambulatory and they were undertaken in the day-stay unit. No patient required admission to the hospital within the following days; the only minor complications reported by 25% of the patients were postprocedure low-back and leg pain or discomfort, which always lasted fewer than 4 days and responded to oral NSAIDs.

DISCUSSION

The major causes of pain persistence in patients with FBSS are epidural fibrosis, disc herniation, and stenosis. Epiduroscopy obtains long-term good results in approximately 40% of patients with severe FBSS who have not responded to other conventional treatments such as epidurolysis with Racz catheter or radiofrequency (9,10). When these problems are located at the intervertebral foramen level, it can be difficult to advance the epiduroscope into the lateral recess and pass the foramen or reach the anterior epidural space. These circumstances encouraged us to develop an alternative endoscopic approach to treating these patients.

Transforaminal epiduroscopy must be considered as an alternative approach to caudal or interlaminar epiduroscopy when conventional epidurolysis or other treatments, such as dorsal root ganglion radiofrequency and transforaminal blocks, have failed and clearly shown concordant pain and fibrosis; or for filling defects located at the foraminal level. In these specific cases, we consider this technique easier to perform and less invasive than others. What is more important is that, for these patients, transforaminal epiduroscopy showed significantly better long-term outcomes (54%) compared to other conventional approaches. Transforaminal endoscopy can also be employed as a consecutive technique in the same procedure when we are unable to reach the epidural recess or the foramen from inside to outside with the caudal or interlaminar approaches.

Our preliminary experience showed that transforaminal epiduroscopy is less aggressive than conventional epiduroscopy, with a very low rate of minor complications (e.g., postprocedure low-back and leg pain) similar to that described in conventional epidurolysis. There were no dural punctures, neurological symptoms associated with a high level of intracranial pressure during the injection of saline boluses, or postprocedure infections. Two aspects of the procedure could explain the absence of complications: (a) the low volume of saline needed to perform the technique (37 mL; range, 22–55 mL) when compared with other techniques that require moderate volumes ranging from 60 (13) to 298 (14) mL but reaching ranges of 350 (15) to 650 mL (16) in caudal approaches; and (b) the shorter length that the epiduroscopy must be advanced. In our experience, the adhesions causing radicular pain were located in the first 1 to 2 cm from the foraminal level.

Most of our patients had severe fibrosis. In all of these patients, a percutaneous adhesiolysis had previ-

Transforaminal Epiduroscopy in Patients with FBSS

Table 1. Clinical data of the patients submitted to transforaminal epiduroscopy.

Patient No., Gender	Age (yrs)	NRS-11 basal	No. of operations	MRI	Foramen Level L/R	Epiduroscopy (results, duration, volume)	NRS-11 1 mo	NRS-11 6 mos	NRS-11 12 mos
1. M	67	8	1	L4-S1 posterior arthrodesis. L4-L5 R foraminal stenosis	L4-L5 R	Grade III adhesions Fibroinflammatory tissue, 25 min, 35 mL	3	4	3
2. M	74	9	2	L4-S1 posterior arthrodesis. Disc protrusion L5-S1 L	L5-S1 L	Grade III adhesions 40 min, 30 mL	5	8	New surgery
3. M	84	7	2	L3-S1 posterior arthrodesis. Adhesions/disc bulged L3-L4 R	L3-L4 R	Grade IV adhesions 35 min, 35 mL	3	5	5
4. F	66	8	1	L4-L5 R laminectomy. Adhesions L4-L5 R	L4-L5 R	Grade III adhesions 15 min, 22 mL	3	2	2
5. M	48	8	1	L3-L4 L foraminotomy & strong adhesions	L3-L4 L	Grade IV adhesions. Thick scar septum 35 min, 25 mL	7	7	SCS
6. F	72	9	2	L3-L5 posterior arthrodesis Adhesions/disc foraminal protrusion L4-L5 R	L4-L5 R	Grade IV adhesions 30 min, 25 mL	4	3	2
7. F	49	8	3	Adhesions L5-S1 R. Disc herniation L5-S1	L5-S1 R	Grade III adhesions 30 min, 30 mL	5	7	New surgery
8. M	57	7	1	L5-S1 L laminectomy. Adhesions L5-S1 L. Disc protrusion L5-S1	L5-S1 L	Grade III adhesions Fibroinflammatory tissue, 20 min, 40 mL	1	1	1
9. F	69	8	1	L4-L5 R laminectomy Adhesions L4-L5 R foraminal stenosis	L4-L5 R	Grade II adhesions. Inflamed L4 root. Very painful access, 20 min, 42 mL	2	6	New surgery
10. M	64	7	2	L4-L5 posterior arthrodesis. L4-L5 R adhesions	L4-L5 R	Grade III adhesions 20 min, 43 mL	1	0	0
11. F	43	9	1	L4-S1 posterior arthrodesis & L5-S1 intersomatic prosthesis	L5-S1 R	Grade III adhesions 30 min, 55 mL	4	4	2
12. F	42	8	5	L5-S1 posterior arthrodesis. Adhesions L5-S1 L	L5-S1 L	Grade IV adhesions. No access to epidural space due to strong scar tissue, 20 min, 30 mL	7	8	SCS
13. M	40	7	1	L5-S1 posterior arthrodesis	L5-S1 R	Grade IV adhesions 20 min, 32 mL	3	4	3
14. F	77	8	1	L4-L5 posterior arthrodesis	L4-L5 L	Grade III adhesions 30 min, 51 mL	2	2	2
15. M	43	7	1	L5-S1 posterior arthrodesis & intersomatic prosthesis. Adhesions L5-S1 R	L5-S1 R	Grade III adhesions 20 min, 40 mL	5	6	7
16. M	58	8	2	L3-S1 posterior arthrodesis	L5-S1 L	Grade IV adhesions 30 min 40 mL	2	3	3

Table 1 (cont.). *Clinical data of the patients submitted to transforaminal epiduroscopy.*

Patient No., Gender	Age (yrs)	NRS-11 basal	No. of operations	MRI	Foramen Level L/R	Epiduroscopy (results, duration, volume)	NRS-11 1 mo	NRS-11 6 mos	NRS-11 12 mos
17. F	41	8	1	L4-L5 laminectomy Adhesions L4-L5 R	L4-L5 R	Grade II adhesions 25 min 40 mL	3	2	3
18. F	72	8	4	L3-S1 posterior arthrodesis	L5-S1 R	Grade IV adhesions 40 min 53 mL	7	7	SCS
19. M	80	7	1	L5-S1 L laminectomy L5-S1 L adhesions/ bulged disc	L5-S1 L	Grade III adhesions 30 min 30 mL	3	3	2
20. M	75	8	1	L4-L5 laminectomy	L4-L5 R	Grade III adhesions 35 min 40 mL	7	8	New surgery
21. F	47	9	1	L3-L5 posterior arthrodesis	L3-L4 R	Grade III adhesions Fibroinflammatory tissue 35 min 30 mL	4	3	2
22. M	60	7	1	L4-S1 posterior arthrodesis Disc protrusion L5-S1	L4-L5 L	Grade III adhesions 40 min 50 mL	3	5	4
23. M	54	7	2	L4-L5 posterior arthrodesis	L4-L5 R	Grade III adhesions Very painful access 30 min 45 mL	5	7	5
24. F	51	8	2	L5-S1 posterior arthrodesis	L5-S1 R	Grade III adhesions 25 min 25 mL	2	1	2

(M, male; F, female; NRS-11, Numeric Rating Scale; L/R: L, left; R, right).

ously been performed unsuccessfully. In our experience, we find the endoscopic procedures more effective than percutaneous adhesiolysis in FBSS treatment (8,10). In fact, we only perform spinal endoscopy when percutaneous adhesiolysis and radiofrequency have failed, which allows us to improve the condition of a significant percentage of patients otherwise submitted to spinal cord stimulation or other palliative treatments. However, systematic reviews and a meta-analysis still support a stronger level of evidence for percutaneous adhesiolysis than for spinal endoscopy (17).

Nonendoscopic transforaminal adhesiolysis in patients with FBSS has already been described (16). The technique was performed on 2 patients by using a 3-Fr Fogarty catheter advanced from outside to inside under fluoroscopy control, and the balloon was repeatedly inflated and deflated with contrast medium. The patients

showed functional and pain improvement. In this sense, transforaminal epiduroscopy provides a safer way of perineural fibrosis detachment.

Bosscher and Heavner (18) have proposed a technique called Percutaneous Ablation and Curettage and Inferior Foraminotomy (PACIF), which combines conventional epiduroscopy with an outside to inside 10 F dilator advanced at the suprapedicular level, in the triangle of the Kambin area, into the lateral recess and ventral epidural space, disrupting structures such as the cribiform fascia and the peridural membrane. The authors speculate that the peridural membrane, a fibrous layer that covers the internal orifice of the suprapedicular canal, is involved in lumbar pain. The peridural membrane originates from the perichondrium and could be richly innervated, as could be the cribiform fascia or the operculum of Forrestier (19). This

procedure was performed on five nonoperated patients with good results. PACIF could be performed by using transforaminal epiduroscopy as we described. It could open transforaminal epiduroscopy to the treatment of nonoperated patients suffering low back pain.

On the other hand, patients with selective radicular pain related to foraminal pathology (disc herniation, foraminal stenosis) and no response to other treatments could be considered in the future for transforaminal epiduroscopy.

In conclusion, we present a new approach to epiduroscopy via a transforaminal approach. Our preliminary results have shown that it could be useful for patients with FBSS located at a foraminal level. Moreover, this procedure is easier to perform, safer, and shows better long-term results than other spinal endoscopic procedures. Additional studies are warranted to accurately evaluate this interventional technique. Its usefulness for nonoperated patients must also be further investigated.

REFERENCES

- Burman MS. Myeloscopy or direct visualization of the spinal cord. *J Bone Joint Surg* 1931; 13:695-696.
- Poole JL. Direct visualization of the dorsal nerve roots of the cauda equine by means of a myeloscope. *AMA Arch Neurol Psychiatry* 1938; 39:1308-1312.
- Ooi Y, Morisaki N. Intrathecal lumbar endoscope. *Clin Orthop Surg (Japan)* 1969; 4:295-297.
- Blomberg RG. A method of epiduroscopy and spinaloscopy: Presentation of preliminary results. *Acta Anaesthesiol Scand* 1985; 29:113-116.
- Heavner JE, Cholkhavatia S, Kizelshteyn G. Percutaneous evaluation of the epidural and subarachnoid space with the fiberscope. *Reg Anesth* 1991; 15(S):85.
- Shimoji K, Fujioka H, Onodera M, Hokari T, Fukuda S, Fujinara N, Hatori T. Observation of spinal canal and cisternae with the newly developed small-diameter, flexible fiberscopes. *Anesthesiology* 1991; 75:341-344.
- Saberski LR, Kitahata LM. Direct visualization of the lumbosacral epidural space through the sacral hiatus. *Anesth Analg* 1995; 80:839-840.
- Avellanal M, Diaz-Reganon G. Interlaminar approach for epiduroscopy in patients with failed back surgery syndrome. *Br J Anaesth* 2008; 101:244-249.
- Kallewaard JW, Vanelderden P, Richardson J, Van Zundert J, Heavner J, Groen GJ. Epiduroscopy for patients with lumbosacral radicular pain. *Pain Pract* 2014; 14:365-377.
- Avellanal M, Diaz-Reganon G, Orts A, Soto S. One-year results of an algorithmic approach for managing failed back surgery syndrome. *Pain Res Manag* 2014; 19:313-316.
- Avellanal M, Diaz-Reganon G, Orts A, Gonzalez-Montero L, De Andrés Ares J. Epiduroscopy: Complications and troubleshooting. *Tech Reg Anesth Pain Manag* 2014; 18:35-39.
- Bosscher HA, Heavner JE. Incidence and severity of epidural fibrosis after back surgery: An endoscopic study. *Pain Pract* 2010; 10:18-24.
- Bosscher HA, Heavner JE. Lumbosacral epiduroscopic findings predict treatment outcome. *Pain Pract* 2014; 14:506-514.
- Igarashi T, Hirabayashi Y, Seo N, Saitoh K, Fukuda H, Suzuki H. Lysis of adhesions and epidural injection of steroid/local anaesthetic during epiduroscopy potentially alleviate low back and leg pain in elderly patients with lumbar spinal stenosis. *Br J Anaesth* 2004; 93:181-187.
- Raffaelli W, Righetti D. Surgical radio-frequency epiduroscopy technique (R-ResAblator) and FBSS treatment: Preliminary evaluations. *Acta Neurochir Suppl* 2005; 92:121-125.
- Hwang B-Y, Ko H-S, Suh J-H, Shin J-W, Lee, J-G, Lee J-D. Clinical experiences of performing transforaminal balloon adhesiolysis in patients with failed back surgery syndrome: Two cases report. *Korean J Anesthesiol* 2014; 66:169-172.
- Helm S, Racz GB, Gerdesmeyer L, Justiz R, Hayek SM, Kaplan ED, El Terany MA, Knezevic NN. Percutaneous and endoscopic adhesiolysis in managing low back and lower extremity pain: A systematic review and meta-analysis. *Pain Physician* 2016; 19:E245-E281.
- Bosscher HA, Heavner JE. Treatment of common low back pain: A new approach to an old problem. *Pain Pract* 2015; 15:509-517.
- Paz-Fumagalli R, Haughton VM. Lumbar cribiform fascia: Appearance at freezing microtomy and MR imaging. *Radiology* 1993; 187:241-243.

